
Patient:	Smith, John	Accession Number:	LDA-16-007351				
Address:	123 MAIN STREET MEMPHIS, TN 38112	Date of Service (Collection):	8/15/2016				
		Date Received:	8/16/2016				
Gender:	M	DOB:	9/15/1932	Age:	78	MR/Chart:	1234567
Physician:	John Williams, MD	Copies To:					
Client:	Dermatology Associates						

FINAL DIAGNOSIS:

- A. Left Dorsum Hand, Punch
Basal cell carcinoma, nodular type (C44.619)

Comment: The margins are free of the carcinoma in the planes of section examined.

SOURCE OF SPECIMEN: Left dorsum hand, punch
CLINICAL IMPRESSION: 2 cm keratotic plaque; rule out basal cell carcinoma; squamous cell carcinoma

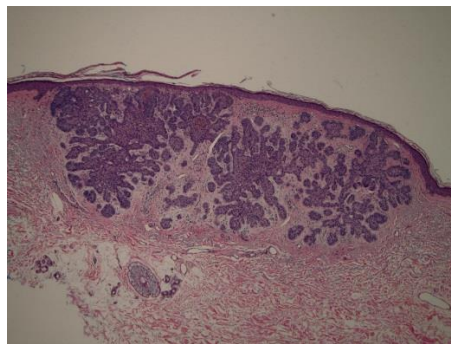
GROSS DESCRIPTION:

- A. Received in formalin are multiple fragments of irregular red-tan skin ranging from 0.3 x 0.2 x 0.1 cm to 0.5 x 0.3 x 0.2 cm. The margin is inked green. Totally submitted. Sections: A1-5. CH/sh

MICROSCOPIC DESCRIPTION:

- A. A poorly circumscribed neoplasm is comprised of basaloid cells in nests exhibiting peripheral palisading and clefting between neoplastic cells and the surrounding stroma. Mitoses are seen.

BW/clj



Left dorsum hand, punch (001)

Barry White, MD
Dermatopathologist
Electronically signed Aug 17, 2016